

Case Report

A Case of Dysphagia and Dysphonia Caused by Diffuse Idiopathic Skeletal Hyperostosis

Ahmet Hamdi Kepekci,^{1,2} Hidayet Sari³

¹Yeni Yuzyil University, Health Occupation High-School Audiometry, Istanbul, Turkey

²Department of Otolaryngology, Meltem Hospital, Istanbul, Turkey

³Department of Physical Therapy and Rehabilitation, Istanbul University, Istanbul, Turkey

Abstract

This report describes a case of diffuse idiopathic skeletal hyperostosis (DISH) leading to dysphagia and dysphonia. DISH causes fibrosis in the ligaments, tendons, and joint capsules, and eventually, secondary osteophytes. DISH is more common in men than women, and is typically seen in those over the age of 50. A 75-year-old female patient who had been diagnosed with DISH presented at the ear, nose, and throat polyclinic for dysphagia and dysphonia, as well as back and neck pain. Endoscopic examination of the larynx revealed a protrusion at the posterior wall of the hypopharynx. Computed tomography (CT) scanning of the larynx and cervical region and a barium swallow were performed. The CT scan showed large osteophytes originating in the anterior part of the second and third cervical vertebrae that were suppressing the laryngeal structures and the epiglottis. The swallow graphy also indicated suppression and partial blockage of the esophageal passage. The protruding osteophytes had damaged the recurrent laryngeal nerve and caused recurrent laryngeal neuropathy and esophageal inflammation, and fibrosis led to dysphagia and dysphonia. Treatment with oral anti-inflammatory drugs and physiotherapy was initiated and surgical excision of the osteophytes was suggested. In the differential diagnosis of dysphagia and dysphonia, an endoscopic examination of the larynx and the posterior wall of the hypopharynx should be performed, and it is important to consider DISH. Furthermore, a multidisciplinary approach including physiotherapy, neurology, and other related clinics, is essential.

Keywords: Diffuse idiopathic skeletal hyperostosis, dysphagia, dysphonia, forestier disease

Cite This Article: Kepekçi A, Sari H. A Case of Dysphagia and Dysphonia Caused by Diffuse Idiopathic Skeletal Hyperostosis. *EJMO*. 2017; 1(4): 237-239

Diffuse idiopathic skeletal hyperostosis (DISH), also known as Forestier disease, is a degenerative joint disease characterized by large osteophytes on the vertebral column. Clinical signs are generally back pain and, in some cases, dysphagia and dysphonia complaints, as anterior osteophytes can protrude into the esophagus and damage the recurrent laryngeal nerve, causing recurrent laryngeal neuropathy. In the differential diagnosis of dysphagia and dysphonia, it is essential to perform an endoscopic examination of the posterior wall of the hypopharynx and the larynx.

Presently described is a case of DISH that was a rare cause of dysphagia and dysphonia.

Case Report

A 75-year-old female patient with DISH was referred to the ear, nose, and throat polyclinic for complaints of dysphagia and dysphonia. An endoscopic examination of the larynx showed a protrusion at the posterior wall of the hypopharynx. A CT scan of the larynx and the cervical region and a barium swallow were performed. The CT scan revealed large osteophytes originating in the anterior part of the second and third cervical vertebrae that suppressed the laryngeal structures and the epiglottis (Fig. 1). The swallow graphy also indicated that there was suppression of the esophageal passage and partial blockage (Fig. 2). These findings suggested that these cervical osteophytes were

Address for correspondence: Ahmet Hamdi Kepekci, MD. Haznedar Mahallesi, Ergene Sokagi, No: 52, Gungoren, Istanbul, Turkey

Phone: +90 212 644 22 00 **E-mail:** ahmethamdi.kepekci@yeniyyuzuil.edu.tr

Submitted Date: September 02, 2017 **Accepted Date:** October 15, 2017 **Available Online Date:** October 27, 2017

©Copyright 2017 by Eurasian Journal of Medicine and Oncology - Available online at www.ejmo.org



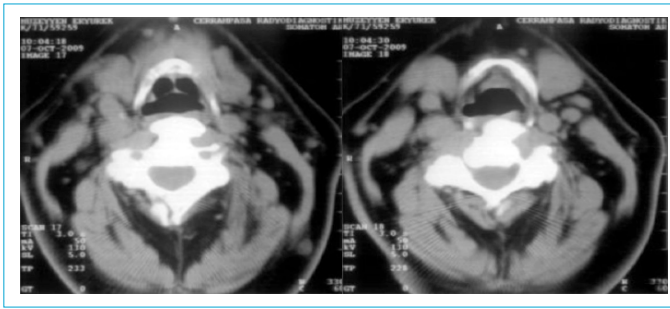


Figure 1. The computed tomography scan of the larynx and cervical region depicting large anterior osteophytes compressing the esophagus and the larynx.

the primary cause of the dysphagia and dysphonia. Treatment with oral anti-inflammatory drugs and physiotherapy was initiated and surgical excision of the osteophytes by a neurosurgeon was suggested.

Discussion

DISH was first described by Jacques Forestier and Jaume Rotes-Querol in 1950. Cervical osteophytes are a common finding in elderly patients, occurring in approximately one-third of individuals older than 60 years of age, and usually remain asymptomatic.^[1] The prevalence of Forestier's disease is low, with numbers that range between 10% and 35% of male patients older than 70 years^[2], and there is apparently a propensity for it to be seen in Caucasians^[3].

DISH causes the development of fibrosis in the ligaments, tendons, and joint capsules, with the occurrence of secondary osteophytes in the final stage.^[4] This disease generally affects the anterior longitudinal ligament, and less often, the posterior ligaments and paraspinal ligaments.^[1] The thoracic region is affected in 96% of patients, while some 90% of patients are affected in the lumbar region and 78% of patients are affected in the cervical region.^[4-6]

The most common vertebrae involved are C5 to C6 (40%), followed by C4 to C5 (23%), C3 to C4 (14%), and C2 to C3 (14%).^[7] The lower cervical vertebrae around the levels of C4, C5, and C6, can impinge on the esophagus, as it is tethered at the level of the cricoid, and the upper cervical spine can impinge on the oropharynx, causing globus, stridor, or respiratory compromise.^[7,8]

Over time, soft tissue fibrosis and calcification may occur in peripheral joints, especially the femur, patella, and metatarsal joints.^[9]

As suggested by its name, the etiology of DISH is unknown, but recent studies have shown that obesity, diabetes mellitus, and hypertension are well-known risk factors.^[10]

Most anterior cervical osteophytes in DISH cases are asymptomatic.^[5,11] Dysphagia is a rare complication in these

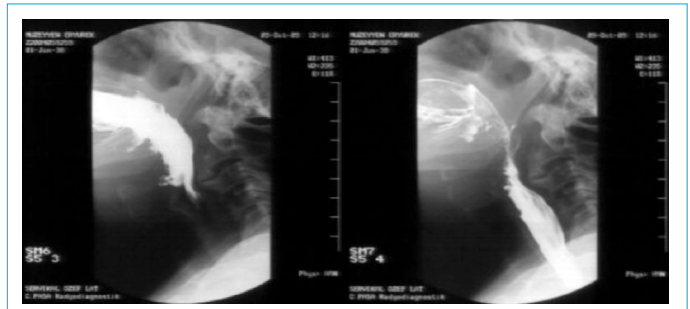


Figure 2. The barium swallow graphy revealed suppression and partial blockage of the esophageal passage.

patients.^[5,9,12] There are several mechanisms for the appearance of dysphagia: 1) the compression effect of anterior osteophytes on esophagus,^[5,11] 2) recurrent laryngeal neuropathy due to neural damage,^[5,10,11] and 3) esophageal inflammation and fibrosis due to the irritation of an anterior osteophyte.^[5,10,11]

In rare patients, dyspnea may also be seen.^[9] In addition to symptoms that appear as a result of neurovascular compression, stridor, the feeling of a foreign body in the throat, cervical pain, cough, a decrease in cervical mobility, otalgia, or odynophagia may occur.^[13] In several cases, recurrent aspiration pneumonia has been reported due to the aspiration of saliva into the larynx and the bronchus.^[5]

In our case, upper level cervical osteophytes had a compression effect on the esophagus and partially blocked the esophageal passage. Large anterior cervical osteophytes were observed on the lateral cervical graphy. According to these findings, we decided that these anterior cervical osteophytes were the cause of the dysphagia and dysphonia as a result of compressing both the esophagus and the larynx.

Conclusion

DISH is a condition that causes fibrosis in the ligaments, tendons, and joint capsules, with the development of secondary osteophytes in later stages.

The protrusion of anterior osteophytes into the esophagus damaged the recurrent laryngeal nerve, causing recurrent laryngeal neuropathy and esophageal inflammation, and fibrosis led to dysphagia and dysphonia.

In the differential diagnosis of dysphagia and dysphonia, an endoscopic examination of the larynx and the posterior wall of the hypopharynx must be performed, and it is important to consider DISH. In addition, a multidisciplinary approach is essential, with the participation of physiotherapy, neurology, and other related clinics.

Disclosures

Informed Consent: Written informed consent was obtained from the patient who participated in this study.

Peer-review: Externally peer-reviewed.

Conflict of Interest: None declared.

Authorship contributions: Concept – A.H.K.; Design – A.H.K.; Supervision – A.H.K.; Materials – H.S.; Data collection &/or processing – A.H.K.; Analysis and/or interpretation – A.H.K.; Literature search – A.H.K.; Writing – A.H.K.; Critical review – A.H.K.

References

1. Solaroğlu I, Okutan O, Karakuş M, Saygılı B, Beşkonaklı E. Dysphagia due to diffuse idiopathic skeletal hyperostosis of the cervical spine. *Turk Neurosurg* 2008;18:409–11.
2. Jeannon JP, Goldstein DP, Bachar G, Gentili F, Irish JC. Forestier disease causing dysphagia. *J Otolaryngol Head Neck Surg* 2008;37:E11–4.
3. Presutti L, Alicandri-Ciufelli M, Piccinini A, Trebbi M, Marchioni D, Ghidini A, et al. Forestier disease: single-center surgical experience and brief literature review. *Ann Otol Rhinol Laryngol* 2010;119:602–8. [\[CrossRef\]](#)
4. Jayson MI, Menkes CJ. Jacques Forestier. *Spine (Phila Pa 1976)* 1995;20:111–5. [\[CrossRef\]](#)
5. Kos MP, van Royen BJ, David EF, Mahieu HF. Anterior cervical osteophytes resulting in severe dysphagia and aspiration: two case reports and literature review. *J Laryngol Otol* 2009;123:1169–73. [\[CrossRef\]](#)
6. Masiero S, Padoan E, Bazzi M, Ponzoni A. Dysphagia due to diffuse idiopathic skeletal hyperostosis: an analysis of five cases. *Rheumatol Int* 2010;30:681–5. [\[CrossRef\]](#)
7. Hilding DA, Tachdjian MO. Dysphagia and hypertrophic spurring of the cervical spine. *N Engl J Med* 1960;263:11–4. [\[CrossRef\]](#)
8. Papakostas K, Thakar A, Nandapalan V, O'Sullivan G. An unusual case of stridor due to osteophytes of the cervical spine: (Forestier's disease). *J Laryngol Otol* 1999;113:65–7. [\[CrossRef\]](#)
9. Mader R, Sarzi-Puttini P, Atzeni F, Olivieri I, Pappone N, Verlaan JJ, et al. Extraspinal manifestations of diffuse idiopathic skeletal hyperostosis. *Rheumatology (Oxford)* 2009;48:1478–81. [\[CrossRef\]](#)
10. Mader R, Lavi I. Diabetes mellitus and hypertension as risk factors for early diffuse idiopathic skeletal hyperostosis (DISH). *Osteoarthritis Cartilage* 2009;17:825–8. [\[CrossRef\]](#)
11. Carlson ML, Archibald DJ, Graner DE, Kasperbauer JL. Surgical management of dysphagia and airway obstruction in patients with prominent ventral cervical osteophytes. *Dysphagia* 2011;26:34–40. [\[CrossRef\]](#)
12. Oppenlander ME, Orringer DA, La Marca F, McGillicuddy JE, Sullivan SE, Chandler WF, et al. Dysphagia due to anterior cervical hyperosteoophytosis. *Surg Neurol* 2009;72:266–70. [\[CrossRef\]](#)
13. Aslan G, Hamzaoğlu A. Forestier hastalığı ve disfaji. *KBB-Forum* 2007;6:33–6.